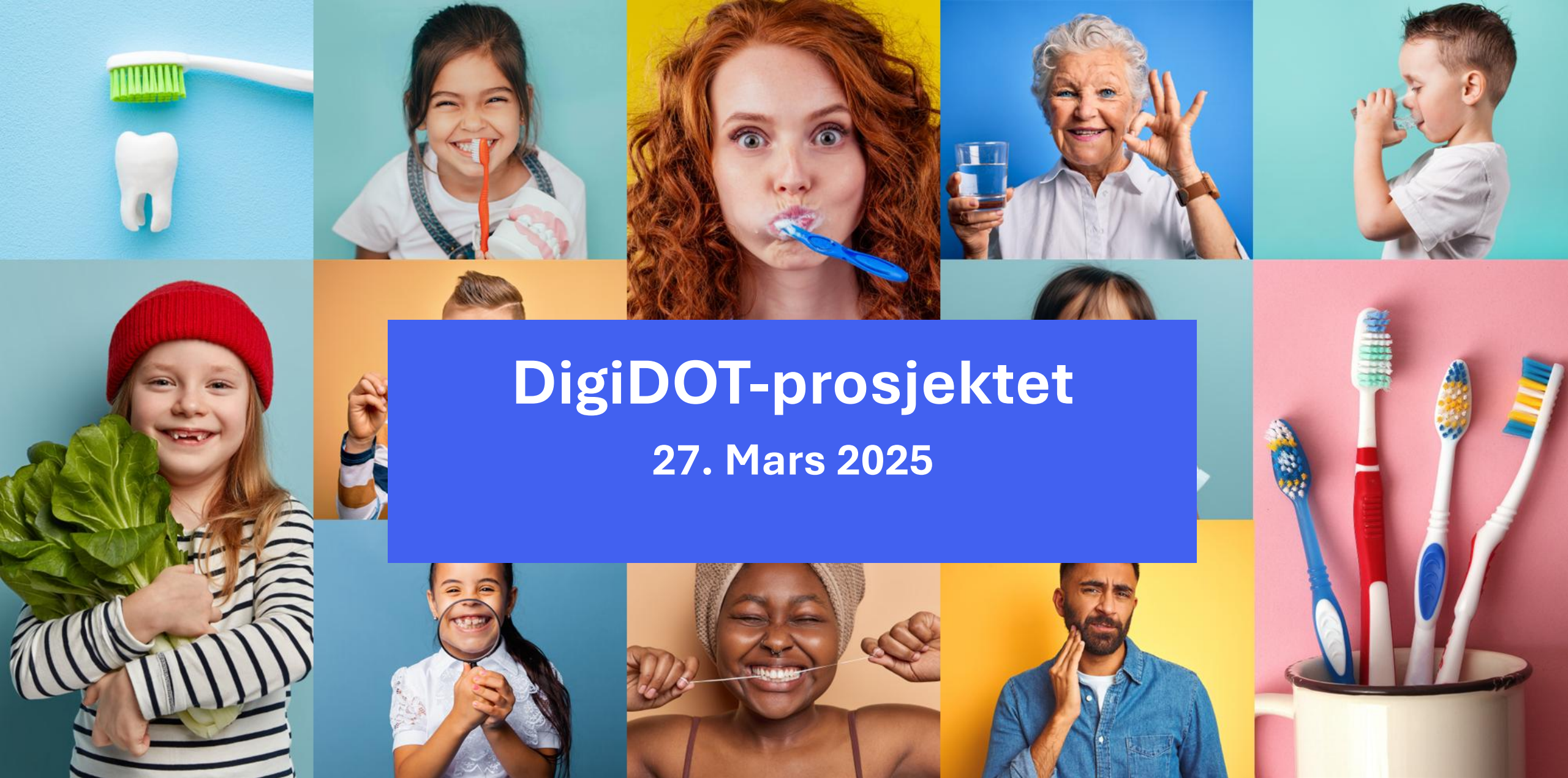




# DigiDOT-prosjektet


27. Mars 2025






# Den offentlige tannhelse- tjenesten i Norge (DOT)

- I 2023 var det over 1,6 millioner innbyggere som mottok regelmessige, individtilpassede tannhelseundersøkelser, og 960 000 personer ble undersøkt og behandlet av helsepersonell i den offentlig tannhelsetjenesten.
- Totalt består tannhelsetjenesten av ca. :
  - 31 %, drøye 3700 årsverk, fordelt på 426 tannklinikker
  - 69 %, omkring 8400 årsverk, er knyttet til den private tannhelsetjenesten

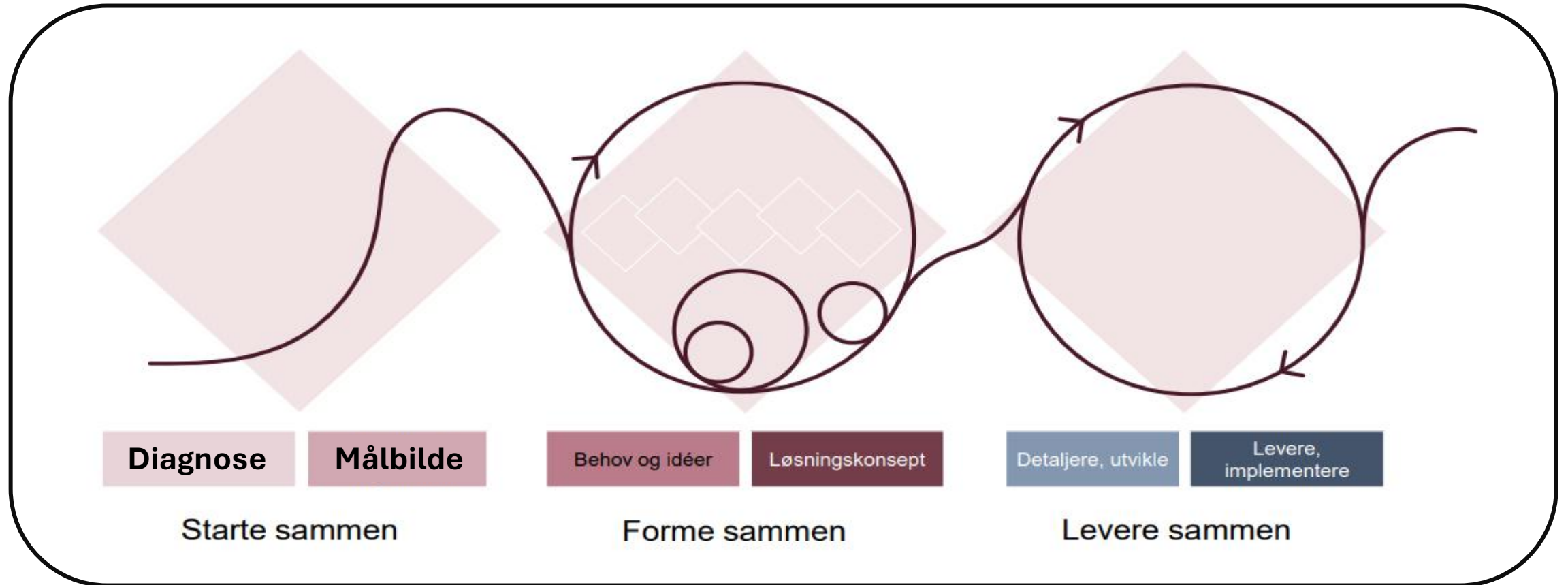


# Digitalisering av den offentlige tannhelsetjenesten

- Mål: utrede mulighetene for en felles anskaffelse av et elektronisk pasientjournalssystem for samtlige fylkeskommuner.
- Hva trenger vi?
- Hva er forutsetningene for en slik anskaffelse?
- Hvordan kan vi best løse en slik anskaffelse?



# Overordnet tilnærming





# Diagnose/ overordnede behov

1

2

3

4



## Munnen er en del av kroppen, i hvert fall digitalt

Digitalisering den offentlige  
tannhelsetjenesten (digi DOT): Diagnose,  
målbilde og juridisk handlingsrom

Rapport fra starte sammen fasen (fase 1)

Versjon 1, april 2024

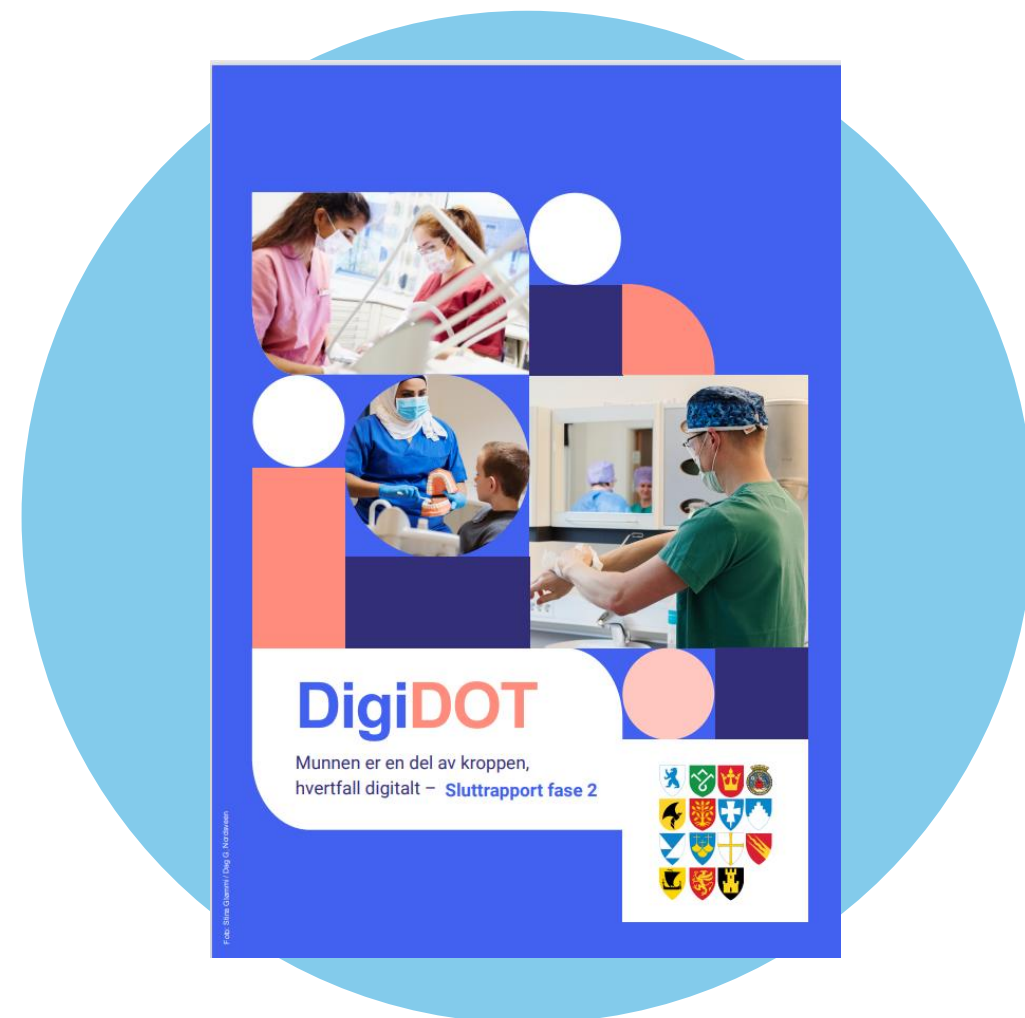Ekstern samhandling 1

Intern samhandling 2

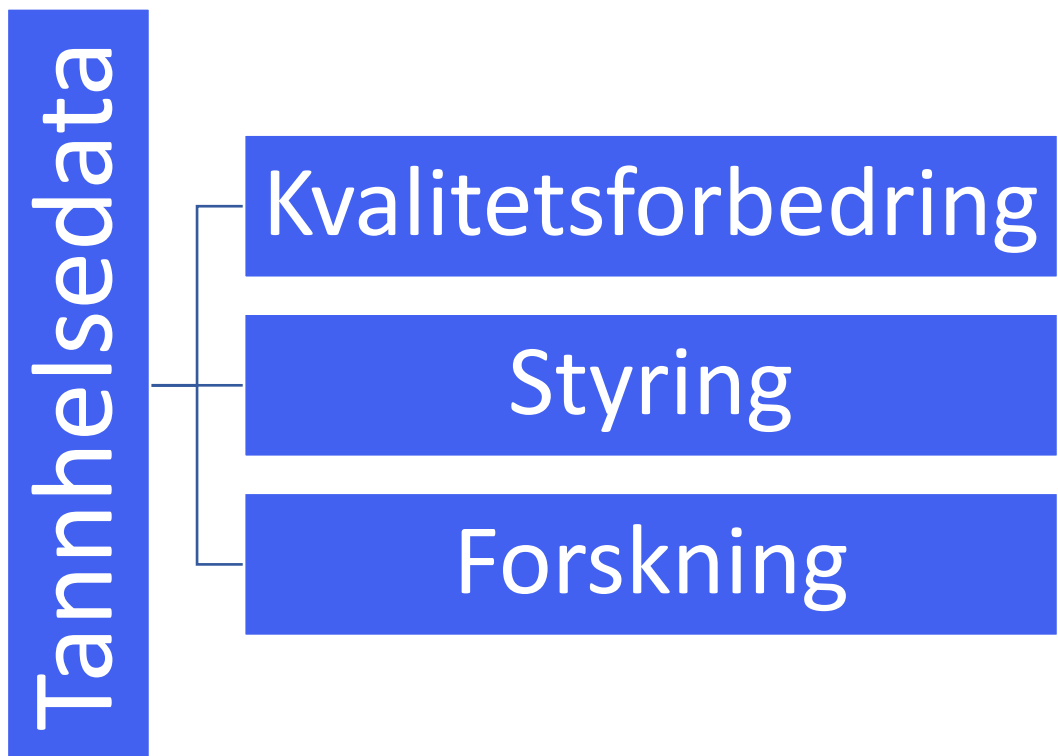
Integrasjoner 3

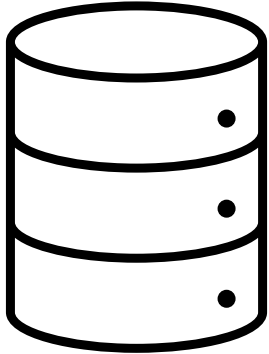
Bedre bruk av data 4

Hvordan løse dette i fellesskap?



# Bedre bruk av data 4





# Pasientinformasjon - Standardisering og struktur



733941004 | Primary active dental caries extending into outer third of dentin |:  
{363698007 | Finding site |=860782001 | ISO designation 33 |}  
{363698007 | Finding site |=56671003 | Incisal surface |}

MIRA Apt pre-registered

- Distal-step primary occlusion
- Flush terminal plane primary occlusion
- Gingivitis assoc with primary herpetic gingivostomatitis
- Hyperaldosteronism
- Mesial-step primary occlusion
- Over-retention of primary tooth
- Postmenopausal osteoporosis
- 30 Primary active extensive dentin caries pulpal 1/3 of dentin
- Primary active extensive dentin caries to the pulp
- Primary active moderate dentin caries middle 1/3 of dentin
- Primary active moderate dentin caries outer 1/3 of dentin
- Primary adrenocortical insufficiency (Addison's disease)
- Primary herpetic gingivostomatitis
- Primary herpetic gingivostomatitis
- Primary non-active dentin caries pulpal 1/3 of dentin
- Primary non-active dentin caries middle 1/3 of dentin
- Primary non-active dentin caries outer 1/3 of dentin
- Primary non-active extensive dentin caries to the pulp
- Primary occlusal trauma
- Sjogren's syndrome (Sicca syndrome)

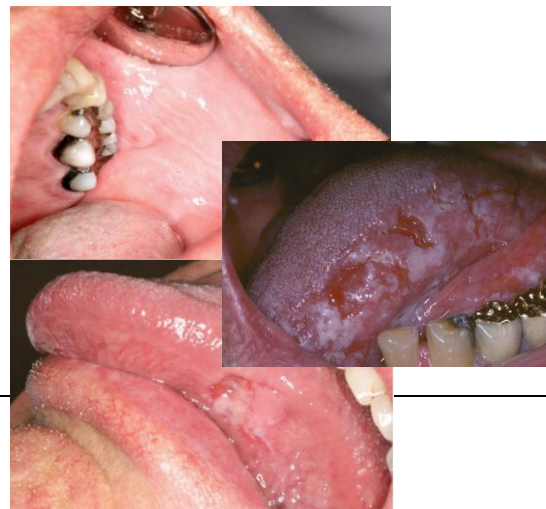
ORAL PATHOLOGY/RADIOLOGY  
Systemic Disease Manifest. Jaw  
Primary adrenocortical insufficiency (Addison's disease)

An adrenal disease characterized by the progressive destruction of the ADRENAL CORTEX, resulting in insufficient production of ALDOSTERONE and HYDROCORTISONE. Clinical symptoms include ANOREXIA; NAUSEA; WEIGHT LOSS; MUSCLE WEAKNESS; and HYPERPIGMENTATION of the SKIN due to increase in circulating levels of ACTH precursor hormone which stimulates MELANOCYTES

Primary adrenocortical insufficiency (disorder)  
Primary hypoadrenalism

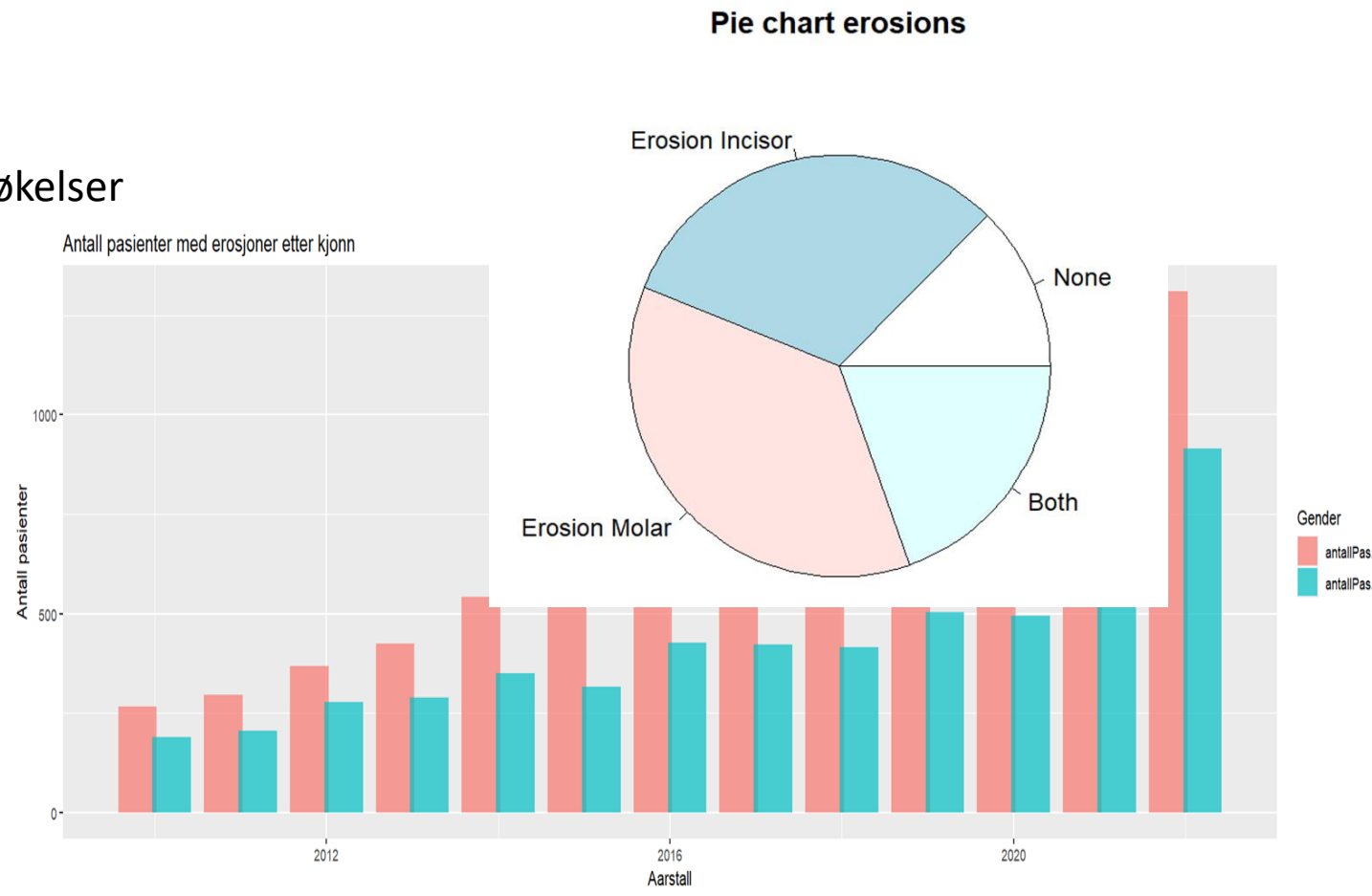
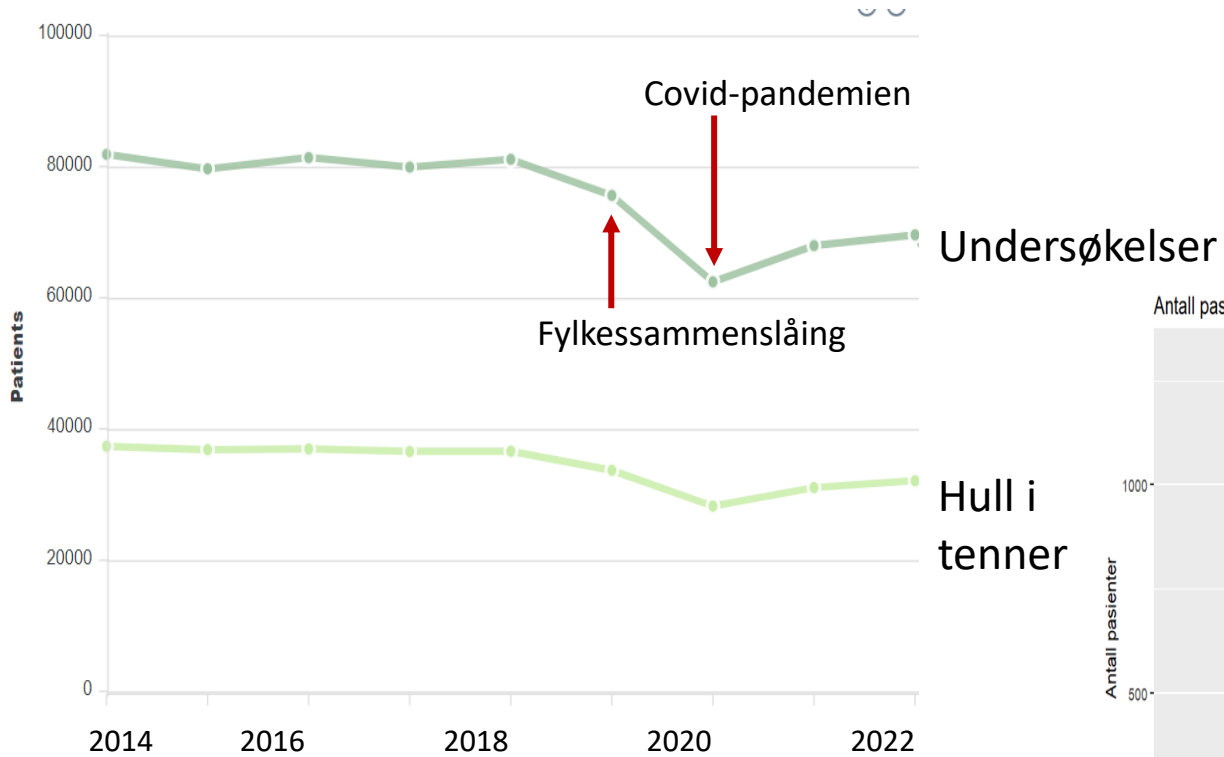
255.41 Glucocorticoid Deficiency

primary|



67795000 | leukoødem i munn |  
[414603003](#) | leukoplaki i munnslimhinne |  
1162767002 | plateepitelkarsinom |





Takk for meg

